

Sonographic cervical length measurement in pregnant women with a cervical pessary

M. GOYA*, L. PRATCORONA*, T. HIGUERAS*, S. PEREZ-HOYOS†, E. CARRERAS* and L. CABERO*

*Maternal-Fetal Medicine Unit, Department of Obstetrics and Gynecology, Hospital Vall d'Hebron, Universidad Autónoma de Barcelona, Barcelona, Spain; †Department of Bio-Statistics, Hospital Vall d'Hebron, Barcelona, Spain

KEYWORDS: cervical length; cervical pessary; preterm birth

ABSTRACT

Objectives The aims of this study were to describe and assess the feasibility of measuring cervical length by standard transvaginal sonography (TVS) and transperineal sonography (TPS) in women with a cervical pessary and compare these measurements with those obtained with a new transvaginal technique.

Methods Measurement of cervical length by TPS was attempted immediately before measurement using TVS in 48 women with a cervical pessary at between 22 and 23 weeks' gestation. The TVS procedure consisted of two types of measurement: in the first, the probe was placed on the anterior fornix (standard technique) and in the second, the probe was inserted into the pessary to touch the anterior cervical lip (new technique). Two physicians consecutively performed these procedures and compared the measurements obtained. Intraclass correlation coefficients (ICCs) with 95% CI were used to evaluate interobserver reliability, and Bland–Altman analysis was used to assess interobserver agreement.

Results In total, 258 measurements (obtained from 43 women) were analyzed. Interobserver ICCs of the measurements obtained were 0.58 (95% CI, 0.34–0.75) for TPS, 0.65 (95% CI, 0.44–0.79) for the standard TVS technique and 0.97 (95% CI, 0.95–0.98) for the new TVS technique. Bland–Altman analysis showed small mean differences between measurements obtained by two physicians for the three methods, but with narrower limits of agreements (LOA) for the new TVS technique: TPS mean difference -0.99 mm (95% LOA, -13.23 to 11.25 mm), standard TVS technique mean difference -0.23 mm (95% LOA, -10.90 to 10.44 mm) and new TVS technique mean difference -0.01 mm (95% LOA, -2.57 to 2.55 mm). It was apparent from the images

obtained that the external os was not visible in 89% of cases when either the TPS or standard TVS technique was used. However, the external os was visible in all cases when the new TVS method was used.

Conclusions We propose a new technique for measuring and monitoring cervical length in women with a cervical pessary that provides improved visualization of the cervix and increased reliability in comparison to established techniques. Copyright © 2011 ISUOG. Published by John Wiley & Sons, Ltd.

INTRODUCTION

It is well known that a sonographically short cervix is a powerful predictor of spontaneous preterm delivery^{1–12}. Interventions that may play a role in treating women with a short cervical length include cerclage^{13–22}, administration of progesterone^{23–26} and the cervical pessary. The use of a cervical pessary has been described as a possible method of preventing preterm delivery in pregnant women when a short (≤ 25 mm) cervical length is detected around the 20th week of gestation^{27–29}. The cervical pessary is a silicone ring with an internal diameter that matches that of the cervix and an external diameter large enough to wedge the device against the pelvic floor. This effectively rotates the cervix towards the posterior vaginal wall and corrects the cervical angle (Figure 1)²⁸.

Different techniques for measuring cervical length have been described. Using the transabdominal sonographic approach, it is often not possible to obtain an appropriate view of the cervix, particularly if it is short. A full bladder is also required for visualization, which could yield a falsely long cervical length^{30–33}. Transvaginal sonography (TVS) has become the standard method for obtaining

Correspondence to: Dr M. Goya, Hospital Vall d'Hebron – Maternal-Fetal Medicine, Passeig de la vall d'Hebron, 119, Barcelona, 08035, Spain (e-mail: mgoya@vhebron.net)

Accepted: 26 January 2011

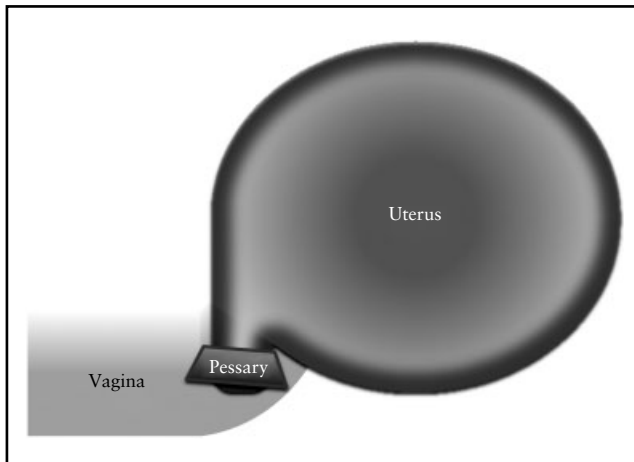


Figure 1 Schematic diagram of a cervical pessary fitted around the cervix with its outer rim on the floor of the pelvis, thus rotating the cervix to the posterior vaginal wall and correcting the cervical angle.

measurements of cervical length, since it provides the observer with a complete view of the entire endocervical canal in the majority of cases^{34,35}. However, in women with a cervical pessary, sonographic visualization of cervical length is difficult owing to the shadow cast by the pessary on the cervix (Figure 2). An alternative technique is transperineal sonography (TPS), but Cicero *et al.*³⁶ demonstrated that visualization with TPS was satisfactory in only 80% of cases.

In view of the inconclusive results using the standard TVS technique, we sought to develop a method of visualizing the cervix in patients with a cervical pessary. We found that good visualization of the cervix is enabled by passing the probe through the space between the pessary and posterior vaginal wall and inserting it just inside the pessary, if possible touching the external cervical os or anterior cervical lip (Figure 3).

The aims of this study were to describe and assess the feasibility of measuring cervical length by TVS and TPS in women with a cervical pessary and to compare the measurements with those obtained with a new transvaginal intrapessary measurement technique.

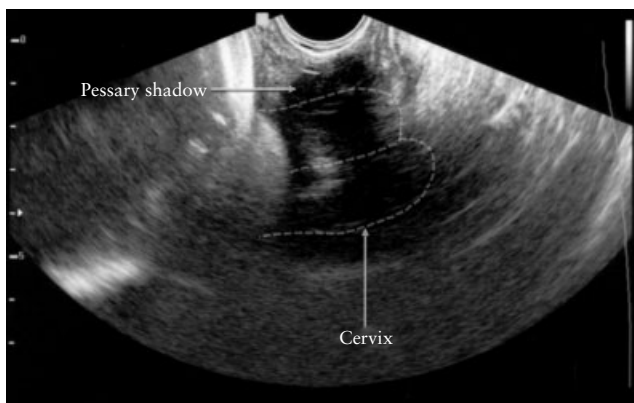


Figure 2 Visualization of cervical length in a woman with a cervical pessary using the standard transvaginal sonographic technique.

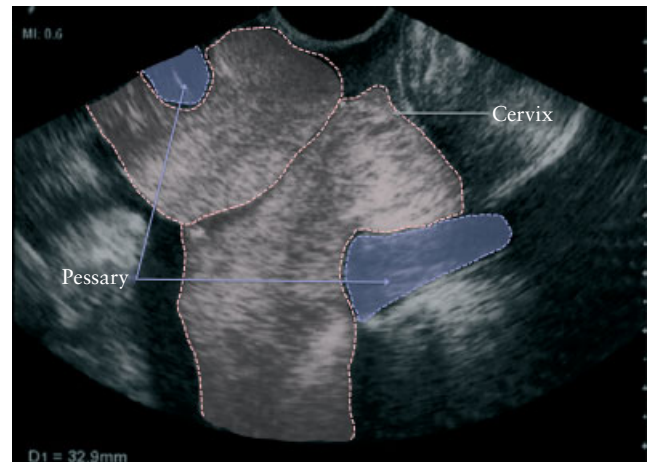


Figure 3 Visualization of cervical length in a woman with a cervical pessary using the new transvaginal sonographic technique.

METHODS

Our center offers women attending for routine antenatal care an ultrasound scan at 18–22 weeks that includes transabdominal sonography of the fetus. At that time, they are offered a TVS scan of the cervix as a screening test for predicting preterm delivery. From 2007 to 2010, women with a short cervix (≤ 25 mm) were invited to participate in an ongoing randomized controlled trial of cervical pessary to prevent preterm birth.

All women gave their written informed consent, and the ethics committee of our hospital approved the study. Cervical pessaries were CE-certified for the indication of preventing preterm delivery (CE0482/EN ISO 13 485: 2003 annex III of the council directive 93/42 EEC). One size was used: 70 × 30 × 32 mm cerclage pessaries (lower external diameter, height and upper internal diameter) (Dr. Arabin GmbH & Co. KG, Witten, Germany). We used a Sonoline G40 ultrasound machine (Siemens Healthcare, Erlangen, Germany) equipped with a 9–4-MHz endovaginal transducer. Participants in this trial who attended the preterm birth clinic at our center underwent monthly cervical-length follow-up by ultrasound.

In order to validate the new technique, 48 of these patients with a cervical pessary were included in this study. In all cases, cervical length was measured by TPS, TVS (standard technique) and TVS using the new technique (transvaginal intrapessary technique) between 22 and 23 weeks' gestation. Two experienced specialists carried out the examination and obtained the three proposed measurements in each case. Systematic evaluation showed that the cervix is best visualized when the probe is passed through the potential space between the pessary and the posterior vaginal wall, and positioned just inside the pessary, if possible touching the external cervical os or the anterior cervical lip (Figure 4). Therefore, it is useful to guide the transducer first towards the sacrum to reach that space and then towards the symphysis. The first five cases were excluded from the analysis, since they were considered to be part of the learning phase of the examiners, leaving 43 participants in the trial.

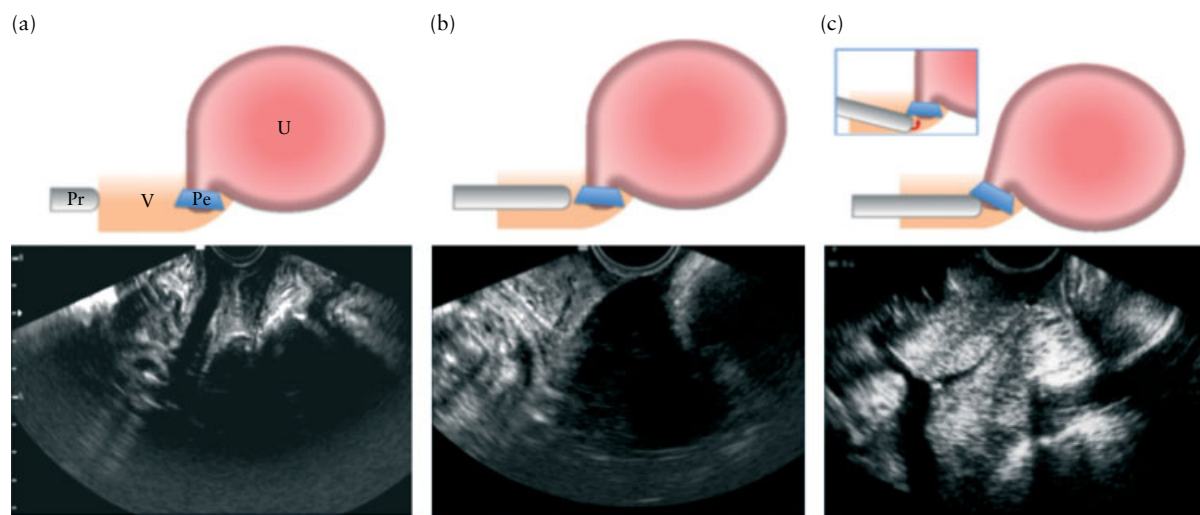


Figure 4 The three different approaches included in the study and the sonographic images they provide. (a) Transperineal measurement. (b) Transvaginal measurement with the probe in the anterior fornix (standard approach); note the shadow of the pessary in the corresponding ultrasound image. (c) The new transvaginal measurement approach proposed: with the probe just inside the pessary, a complete view of the cervical canal is obtained. Pe, pessary; Pr, probe; U, uterus; V, vagina.

Statistical analysis

Intraclass correlation coefficients (ICCs) with 95% CIs^{37,38}, and the Bland–Altman method for assessing agreement, including calculation of the average discrepancy between measurements (mean difference), the 95% limits of agreement (LOA) and the SD of mean difference³⁹, were used to assess interobserver reliability. The Bland–Altman method identifies the boundaries between which measurements are interchangeable, and determines the relationship between the difference in the measurement between observers and the magnitude of the measurement. Data were analyzed using SPSS 16.0 software (SPSS Inc., Chicago, IL, USA).

RESULTS

The mean maternal age of the 43 participants was 33.3 ± 4.67 years. Cervical length was successfully measured transperineally and transvaginally with the standard technique in all cases: 258 measurements were performed and compared (Table 1).

Although it was possible to locate the cervix, pessary and internal cervical os in all cases, the canal and

Table 1 Sonographic cervical length measurements in 43 women with a cervical pessary obtained by two examiners using standard transvaginal sonography (TVS), transperineal sonography (TPS) and a new TVS approach

Technique	Cervical length (mm)	
	Examiner 1	Examiner 2
TPS	23.4 (10.4–40.9)	24.4 (10.2–37.0)
TVS (standard technique)	24.6 (11.7–42.0)	24.8 (13.5–36.9)
TVS (new technique)	19.0 (6.1–28.6)	19.0 (7.0–28.5)

Data are presented as median (range).

external os were hidden by the pessary's shadow; thus, the measurement was taken from the internal os to the end of the pessary's shadow. It was apparent from the images obtained that the external os was not visible in 89% of cases when either the TPS or the standard TVS technique was used. The new procedure, which permitted complete visualization of the canal with both external and internal ora, could not be performed in one of the first five cases (learning period) owing to patient discomfort. In all cases analyzed, the external os and cervical canal were visible when the new TVS method was used.

Interobserver ICCs of the measurements obtained were 0.58 (95% CI, 0.34–0.75) for TPS, 0.65 (95% CI, 0.44–0.79) for the standard TVS technique and 0.97 (95% CI, 0.95–0.98) for the new technique. The new TVS technique showed increased reliability in comparison to the standard TVS and TPS techniques; this difference was statistically significant, as indicated by the lack of overlap between the 95% CI for the new TVS technique and those for the other methods.

Bland–Altman analysis showed small mean differences between measurements obtained by the two physicians for the three methods, but with narrower LOA for the new TVS technique: TPS mean difference -0.99 (95% CI, -2.9 to 0.89) mm, 95% LOA -13.23 to 11.25 mm; standard TVS technique mean difference -0.23 (95% CI, -1.89 to 1.40) mm, 95% LOA -10.90 to 10.44 mm; and new TVS technique mean difference -0.01 (95% CI, -0.40 to 0.38) mm, 95% LOA -2.57 to 2.55 mm (Figure 5).

DISCUSSION

Prospective trials have only recently been started to test the effectiveness of the cervical pessary⁴⁰. We are currently conducting the first randomized controlled trial to test the effectiveness and safety of a cervical pessary for

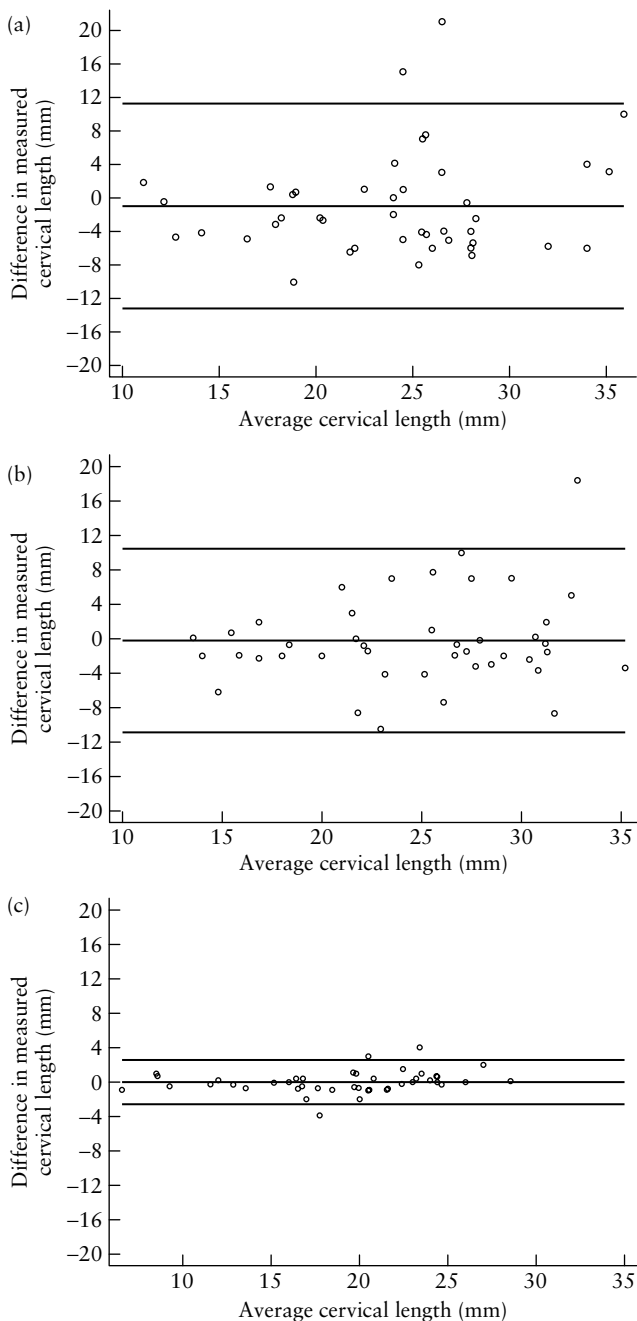


Figure 5 Bland–Altman plots of interobserver difference in measurement of cervical length using transperineal sonography (a), standard transvaginal sonographic (TVS) technique (b) and new TVS technique (c).

the prevention of preterm birth in women with a short cervix (≤ 25 mm). However, placement of a cervical pessary impairs sonographic visualization of the endocervical canal and external os when both TPS and TVS (standard technique) are used. Yet, monitoring cervical length in patients treated with a cervical pessary is important, since it permits assessment of the risk for spontaneous preterm labor and birth.

With this new TVS approach to the measurement of cervical length, the interobserver differences are minimal, while with the other techniques they are significantly greater owing to the shadow cast by the pessary on the

sonographic cervical image, which hinders measurement of the whole cervical canal and only permits measurement from the internal cervical os to the end of the pessary's shadow. The difference between the ICCs of the three methods suggests that the most appropriate method of measurement in patients with a cervical pessary is this new model, since it provides a better view of the cervix.

The new TVS technique is easy to perform; however, we found that the sonographic examination could be painful in patients who have the pessary firmly applied against the posterior vaginal wall. Nonetheless patient discomfort prevented our performing the sonographic examination in only one patient.

The results of this study should be viewed within the context of the following limitations. This is the first study comparing cervical length measurement in pregnant women with a cervical pessary by the two methods published previously: TPS and the standard TVS technique; also, this study included a new method of measuring cervical length in patients with a cervical pessary, i.e. the transvaginal intrapessary technique. As the sample size of this study was only 43 patients, more studies are required to independently confirm our results.

In conclusion, we propose a new TVS technique for examining the uterine cervix in women with a pessary. This technique may be helpful in monitoring cervical length during pregnancy in patients carrying this device and may provide insight into the changes in cervical anatomy which result from the use of a pessary.

ACKNOWLEDGMENT

The Institute Carlos III, Fondo de Investigación Sanitaria (FIS), PI 071086, Spain provided funding for this study. We are grateful to Christine O'Hara for English language correction of the manuscript.

REFERENCES

1. Kushnir O, Vigil DA, Izquierdo L, Schiff M, Curet LB. Vaginal ultrasonographic assessment of cervical length changes during normal pregnancy. *Am J Obstet Gynecol* 1990; **162**: 991–993.
2. Okitsu O, Mimura T, Nakayama T, Aono T. Early prediction of preterm delivery by transvaginal ultrasonography. *Ultrasound Obstet Gynecol* 1992; **2**: 402–409.
3. Iams JD, Goldenberg RL, Meis PJ, Mercer BM, Moawad A, Das A, Thom E, McNellis D, Copper RL, Johnson F, Roberts JM. The length of the cervix and the risk of spontaneous delivery. *N Engl J Med* 1996; **334**: 567–572.
4. Hasegawa I, Tanaka K, Takahashi K, Tanaka T, Aoki K, Torii Y, Okai T, Saji F, Takahashi T, Sato K, Fujimura M, Ogawa Y. Transvaginal ultrasonographic cervical assessment for the prediction of preterm delivery. *J Matern Fetal Med* 1996; **5**: 305–309.
5. Heath VCF, Southall TR, Souka AP, Elisseou A, Nicolaidis KH. Cervical length at 23 weeks of gestation: prediction of spontaneous preterm delivery. *Ultrasound Obstet Gynecol* 1998; **12**: 312–317.
6. Guzman ER, Mellon C, Vintzileos AM, Ananth CV, Walters C, Gipson K. Longitudinal assessment of endocervical canal length between 15 and 24 weeks' gestation in women at risk for

- pregnancy loss or preterm birth. *Obstet Gynecol* 1998; **92**: 31–37.
7. Hassan SS, Romero R, Berry SM, Dang K, Blackwell SC, Treadwell MC, Wolfe HM. Patients with an ultrasonographic cervical length $<$ or $=$ 15 mm have nearly a 50% risk of early spontaneous preterm delivery. *Am J Obstet Gynecol* 2000; **182**: 1458–1467.
 8. To MS, Skentou C, Liao AW, Cacho A, Nicolaides KH. Cervical length and funneling at 23 weeks of gestation in the prediction of spontaneous early preterm delivery. *Ultrasound Obstet Gynecol* 2001; **18**: 200–203.
 9. Owen J, Yost N, Berghella V, Thom E, Swain M, Dildy GA 3rd, Miodovnik M, Langer O, Sibai B, McNellis D. Mid-trimester endovaginal sonography in women at high risk for spontaneous preterm birth. *JAMA* 2001; **286**: 1340–1348.
 10. To MS, Fonseca EB, Molina FS, Cacho AM, Nicolaides KH. Maternal characteristics and cervical length in the prediction of spontaneous early preterm delivery in twins. *Am J Obstet Gynecol* 2006; **194**: 1360–1365.
 11. To MS, Skentou CA, Royston P, Yu CK, Nicolaides KH. Prediction of patient-specific risk of early preterm delivery using maternal history and sonographic measurement of cervical length: a population-based prospective study. *Ultrasound Obstet Gynecol* 2006; **27**: 362–367.
 12. Matijevic R, Grgic O, Vasilj O. Is sonographic assessment of cervical length better than digital examination in screening for preterm delivery in a low-risk population? *Acta Obstet Gynecol Scand* 2006; **85**: 1342–1347.
 13. Heath VC, Souka AP, Erasmus I, Gibb DM, Nicolaides KH. Cervical length at 23 weeks of gestation: the value of Shirodkar suture for the short cervix. *Ultrasound Obstet Gynecol* 1998; **12**: 318–322.
 14. Guzman ER, Forster JK, Vintzileos AM, Ananth CV, Walters C, Gipson K. Pregnancy outcomes in women treated with elective versus ultrasound-indicated cervical cerclage. *Ultrasound Obstet Gynecol* 1998; **12**: 323–327.
 15. Althuisius SM, Dekker GA, van Geijn HP, Bekedam DJ, Hummel P. Cervical incompetence prevention randomized cerclage trial (CIPRACT): study design and preliminary results. *Am J Obstet Gynecol* 2000; **183**: 823–829.
 16. Hibbard JU, Snow J, Moawad AH. Short cervical length by ultrasound and cerclage. *J Perinatol* 2000; **20**: 161–165.
 17. To MS, Palaniappan V, Skentou C, Gibb D, Nicolaides KH. Elective cerclage vs. ultrasound-indicated cerclage in high-risk pregnancies. *Ultrasound Obstet Gynecol* 2002; **19**: 475–477.
 18. Belej-Rak T, Okun N, Windrim R, Ross S, Hannah ME. Effectiveness of cervical cerclage for a sonographically shortened cervix: a systematic review and meta-analysis. *Am J Obstet Gynecol* 2003; **189**: 1679–1687.
 19. To MS, Alfirevic Z, Heath VC, Cicero S, Cacho AM, Williamson PR, Nicolaides KH. Cervical cerclage for prevention of preterm delivery in women with short cervix: randomised controlled trial. *Lancet* 2004; **363**: 1849–1853.
 20. Berghella V, Odibo AO, Tolosa JE. Cerclage for prevention of preterm birth in women with a short cervix found on transvaginal ultrasound examination: a randomized trial. *Am J Obstet Gynecol* 2004; **191**: 1311–1317.
 21. Romero R, Espinoza J, Erez O, Hassan S. The role of cervical cerclage in obstetric practice: can the patient who could benefit from this procedure be identified? *Am J Obstet Gynecol* 2006; **194**: 1–9.
 22. Owen J, Hankins G, Iams JD, Berghella V, Sheffield JS, Perez-Delbov A, Egerman RS, Wing DA, Tomlinson M, Silver R, Ramin SM, Guzman ER, Gordon M, How HY, Knudtson EJ, Szychowski JM, Cliver S, Hauth JC. Multicenter randomized trial of cerclage for preterm birth prevention in high-risk women with shortened midtrimester cervical length. *Am J Obstet Gynecol* 2009; **201**: 375.e1–8.
 23. Fonseca EB, Celik E, Parra M, Singh M, Nicolaides KH. Progesterone and the risk of preterm birth among women with a short cervix. *N Engl J Med* 2007; **357**: 462–469.
 24. DeFranco EA, O'Brien JM, Adair CD, Lewis DF, Hall DR, Fusey S, Soma-Pillay P, Porter K, How H, Schakis R, Eller D, Trivedi Y, Vanburen G, Khandelwal M, Trofatter K, Vidvadhari D, Vijayaraghavan J, Weeks J, Dattel B, Newton E, Chazotte C, Valenzuela G, Calda P, Bsharat M, Creasy GW. Vaginal progesterone is associated with a decrease in risk for early preterm birth and improved neonatal outcome in women with a short cervix: a secondary analysis from a randomized, double-blind, placebo-controlled trial. *Ultrasound Obstet Gynecol* 2007; **30**: 697–705.
 25. O'Brien JM, DeFranco EA, Adair CD, Lewis DF, Hall DR, How H, Bsharat M, Creasy GW; Progesterone Vaginal Gel Study Group. Effect of progesterone on cervical shortening in women at risk for preterm birth: secondary analysis from a multinational, randomized, double-blind, placebo-controlled trial. *Ultrasound Obstet Gynecol* 2009; **34**: 653–659.
 26. Hassan SS, Romero R, Vidyadhari D, Fusey S, Baxter JK, Khandelwal M, Vijayaraghavan J, Trivedi Y, Soma-Pillay P, Sambarey P, Dayal A, Potapov V, O'Brien J, Astakhov V, Yuzko O, Kinzler W, Dattel B, Sehdev H, Mazheika L, Manchulenko D, Gervasi MT, Sullivan L, Conde-Agudelo A, Phillips JA, Creasy GW; for the PREGNANT Trial. Vaginal progesterone reduces the rate of preterm birth in women with a sonographic short cervix: a multicenter, randomized, double-blind, placebo-controlled trial. *Ultrasound Obstet Gynecol* 2011; **38**: 18–31.
 27. Newcomer J. Pessaries for the treatment of incompetent cervix and premature delivery. *Obstet Gynecol Surv* 2000; **55**: 443–448.
 28. Arabin B, Halbesma JR, Vork F, Hübener M, van Eyck J. Is treatment with vaginal pessaries an option in patients with a sonographically detected short cervix? *J Perinat Med* 2003; **31**: 122–133.
 29. Acharya G, Eschler B, Grønberg M, Hentemann M, Ottersen T, Maltau JM. Noninvasive cerclage for the management of cervical incompetence: a prospective study. *Arch Gynecol Obstet* 2006; **273**: 283–287.
 30. To MS, Skentou C, Cicero S, Nicolaides KH. Cervical assessment at the routine 23-weeks' scan: problems with transabdominal sonography. *Ultrasound Obstet Gynecol* 2000; **15**: 292–296.
 31. Anderson HF. Transabdominal and transvaginal ultrasonography of the uterine cervix during pregnancy. *J Clin Ultrasound* 1991; **19**: 77–83.
 32. Bowie JD, Andreotti RF, Rosenberg ER. Sonographic appearance of the uterine cervix in pregnancy: the vertical cervix. *AJR Am J Roentgenol* 1983; **140**: 737–740.
 33. Podobnik M, Bulic M, Smiljanic N, Bistricki J. Ultrasonography in the detection of cervical incompetency. *J Clin Ultrasound* 1998; **13**: 383–391.
 34. Anderson HF, Nugent CE, Wanty SD, Hayashi RH. Prediction of risk for preterm delivery by ultrasonographic measurement of cervical length. *Am J Obstet Gynecol* 1990; **163**: 859–867.
 35. Sonek J, Shellhaas C. Cervical sonography: a review. *Ultrasound Obstet Gynecol* 1998; **11**: 71–78.
 36. Cicero S, Skentou CA, Souka A, To MS, Nicolaides KH. Cervical length at 22–24 weeks of gestation: comparison of transvaginal and transperineal-translabial ultrasonography. *Ultrasound Obstet Gynecol* 2001; **17**: 335–340.
 37. Bartko JJ. The intraclass correlation coefficient as a measure of reliability. *Psychol Rep* 1966; **19**: 3–11.
 38. Shrout PE, Fleiss JL. Intraclass correlations: uses in assessing rater reliability. *Psychol Bull* 1979; **86**: 420–428.
 39. Bland JM, Altman DG. Statistical methods for assessing agreement between two methods of clinical measurement. *Lancet* 1986; **1**: 307–310.
 40. Abdel-Aleem H, Shaaban OM, Abdel-Aleem MA. Cervical pessary for preventing preterm birth. *Cochrane Database Syst Rev* 2010; Sep 8; (9): CD007873.